

Prevalence of incomplete ossification of the humeral condyle and other abnormalities of the elbow in English Springer Spaniels

A. P. Moores; P. Agthe; I. A. Schaafsma

Anderson Moores Veterinary Specialists, The Granary, Bunstead Barns, Poles Lane, Hursley, Winchester, Hampshire, UK

Keywords

Incomplete ossification, humeral condyle, coronoid disease, elbow, computed tomography, English Springer Spaniel

Summary

Objectives: To determine the prevalence of incomplete ossification of the humeral condyle (IOHC) and other osseous abnormalities of the elbow in English Springer Spaniels with no history of lameness.

Methods: Prospective observational study of English Springer Spaniels with no recent history of lameness. Computed tomography scans of both elbows were obtained from dogs older than six months of age which were anaesthetized or sedated for reasons unrelated to this study. Computed tomography scans were reviewed for the presence of IOHC and other abnormalities of the elbow. Radio-ulnar incongruity (RUI) measurements from

normal elbows were compared to elbows with IOHC and elbows with medial coronoid process (MCP) abnormalities.

Results: Computed tomography scans from 50 dogs (100 elbows) were reviewed. The prevalence of IOHC was 14% (8 elbows in 7 dogs). All condylar fissures were incomplete with a mean length of 2.6 mm. Fifty percent of the dogs (44% of elbows) had abnormalities of the medial coronoid process and 60% of the elbows had periarticular osteophytes. Group RUI measurements for IOHC and MCP were not significantly different from normal elbows.

Clinical significance: Small IOHC fissures, periarticular osteophytes and MCP abnormalities may be identified in English Springer Spaniels without forelimb lameness. Abnormalities of the MCP are more common than IOHC.

ondary centres of ossification of the humeral condyle prior to their fusion between eight and 12 weeks of age (3). This has led to the assumption that IOHC is a developmental failure of fusion of these centres, although other authors have suggested it may represent a condylar stress fracture (4). Incomplete ossification of the humeral condyle is also recognized in non-Spaniel breed dogs but it remains a condition most often seen in Spaniels, particularly English Springer Spaniels in the United Kingdom (4–7).

Incomplete ossification of the humeral condyle may be identified with radiography but computed tomography (CT) is more sensitive and specific (8). The CT features of IOHC are a variably-sized hypoattenuating fissure in the sagittal plane of the humeral condyle which is bordered by hyperattenuating (i.e. sclerotic) bone (8).

As well as predisposing to humeral condylar fracture, IOHC can cause lameness in the absence of fracture. However, not all dogs with IOHC demonstrate clinical signs. Incomplete ossification of the humeral condyle may be diagnosed as an incidental finding in the contralateral humeral condyle of dogs with humeral condylar fracture and although some dogs with humeral condylar fracture associated with IOHC show a prodromal lameness of the fractured leg, this is not seen in every case (10). Incomplete ossification of the humeral condyle can therefore go unrecognized and the prevalence of IOHC in the general population is unknown.

It is our clinical experience that English Springer Spaniels are often affected by medial coronoid process (MCP) pathology, sometimes but not always in association with IOHC. Other authors have also reported MCP disease in association with

Correspondence to:

Andy Moores, BVSc, DSAS(Orth), DipECVS, MRCVS
Anderson Moores Veterinary Specialists
The Granary, Bunstead Barns
Poles Lane
Hursley, Winchester, Hampshire SO21 2LL
United Kingdom
Phone: + 44 1962 767920
Fax: + 44 1962 775909
E-mail: andy@andersonmoores.com

Vet Comp Orthop Traumatol 2012; 25: 211–216

doi:10.3415/VCOF-11-05-0066

Received: May 2, 2011

Accepted: November 27, 2011

Pre-published on: January 27, 2012

Presented in part at the BVOA Spring Meeting,
Birmingham, UK, March 2011.

Introduction

The predisposition of Spaniel breed dogs to humeral condylar fractures, particularly during relatively normal activity, is well established although the reason for this predisposition was originally unclear (1, 2). It is now accepted that a condition known as incomplete ossification of the humeral

condyle (IOHC) predisposes the humeral condyle to fracture in some dogs (3). Dogs with IOHC have a sagittal fissure present within the humeral condyle which may completely or partially separate the medial and lateral parts of the condyle. The location of the fissure in IOHC corresponds to the location of the cartilaginous plate that separates the medial and lateral sec-

IOHC and also without IOHC in English Springer Spaniels (6, 8, 9, 11). The prevalence of MCP disease in this breed is however unknown.

The purpose of this study was to identify the prevalence of IOHC, MCP disease, and other osseous abnormalities of the elbow in a sample of English Springer Spaniels without thoracic limb lameness. Additional aims were to determine if dogs with IOHC differed from the rest of the sample population in terms of age and if elbows with either IOHC or MCP abnormalities differed from normal elbows in terms of radioulnar incongruity, with the null hypotheses being that there were no differences for these comparisons.

Materials and methods

English Springer Spaniels were prospectively recruited into the study if they were six months of age or older, had no history of thoracic limb lameness in the six months prior to examination, had never suffered a humeral condylar fracture, and they were being anaesthetised or deeply sedated for another procedure and the additional time required to perform an elbow CT scan was not considered a significant additional risk for the dog. All CT scans were performed with owner consent.

Images were acquired with a dual-slice helical CT scanner^a. Imaging was performed in dorsal recumbency with the thoracic limbs extended cranially and the antebrachii parallel. Both elbows were imaged together, from the proximal antebrachium (distal to the medial coronoid process) to the distal humerus (proximal to the lateral epicondylar crest). The slice thickness was 0.6 mm with 0.4 mm intervals and settings were 120 kV / 80 mA. All images were reconstructed with a bone algorithm.

Images were reviewed on a dedicated CT workstation incorporating a diagnostic quality monitor using a bone setting (window width 450 Hounsfield units, window level 2500 Hounsfield units).

One board-certified orthopaedic surgeon (APM) and two board-certified radi-

ologists (PA, IAS), each experienced in interpreting elbow CT images, reviewed the studies of each elbow. Transverse images and dorsal plane reconstructions were used to assess the medial coronoid process and the humeral condyle. Sagittal reconstructions were used to assess humeroulnar trochlear notch congruity. Images were reviewed in one sitting and a consensus was reached for the presence or absence of the following features:

1. Presence of a hypoattenuating fissure of any size in the mid-sagittal plane of the humeral condyle. The position and size of the line was recorded as well as the presence of adjacent hyperattenuation (sclerosis).
2. Presence of a more diffuse area of hypoattenuation within the humeral condyle not associated with a hypoattenuating fissure.
3. Presence of new bone formation or remodelling along the lateral epicondylar crest
4. Presence of fragmentation, fissuring or abnormal shape of the MCP.
5. Hyperattenuation (sclerosis) or hypoattenuation of the MCP
6. Irregularity of the radial incisure of the ulna at the level of the articular surface
7. Presence of humeral condyle defects consistent with osteochondritis dissecans or erosion of the articular surface (kissing lesion)
8. Humeroulnar incongruity of the trochlear notch
9. Osteophytes

Osteophytes were measured and graded following an ordinal four-point grading system (0 = absent, 1 = <2 mm, 2 = 2–5 mm, and 3 = >5mm) (12).

Semi-objective assessment of radioulnar incongruity (RUI) was assessed by one observer (board-certified radiologist - PA) in images obtained by multiplanar reconstruction. Dorsal plane measurements were obtained at the mid-point of the humeroradial and humero-ulnar articulations at the level of the apex of the medial coronoid process using the method described by Gemmill et al. (13). With this method, the long-axis of the medial coronoid process is subjectively identified, and the dorsal plane aligned at 90° to the long-

axis. Measurements are then obtained 1 mm caudal to the apex (or 0.5 mm caudal to a fissure line if present). Dorsal plane measurements were also obtained at the base of the MCP as described in a further study by Gemmill et al. (14). With this method, the junction between the lateral and medial coronoid processes is identified subjectively and defined as the base of the medial coronoid process. We also took dorsal plane joint space measurements at a point halfway between the base and the apex as previously described (14). Sagittal measurements were obtained 1 mm from either side of the radioulnar articulation as previously described (14). A RUI measurement was calculated (RUI = humeroradial measurement – humeroulnar measurement) for each of the four reconstructions (3 dorsal plane, 1 sagittal).

Statistical tests were performed with a commercial software package^b. Data were tested for normality via the Kolmogorov-Smirnov test and a two-tailed unpaired t-test used to compare means if data fulfilled normality. A Mann-Whitney test was used if either data set did not fulfil normality.

The mean age of dogs with and without IOHC was compared via a two-tailed unpaired t-test.

Three groups of elbows were identified for RUI comparisons; CT-normal elbows, elbows with evidence of MCP disease (MCP fragmentation, MCP fissures, abnormal MCP shape, irregular radial incisure of the ulna, hypoattenuation or hyperattenuation of the MCP) and IOHC-positive elbows. For each RUI measurement, the mean of the MCP disease group and of the IOHC group were compared with the mean of the normal group with the Mann-Whitney test. Values of $p < 0.05$ were considered significant for all tests.

Results

Fifty-one dogs were recruited into the study but only 50 dogs (100 elbows) were included in the final analysis due to movement blur compromising the CT images in

^a HiSpeed CT/e Dual: General Electric Medical Systems, Milwaukee, WI, USA

^b InStat version 3.10 for Windows: GraphPad Software, La Jolla, California, USA

Table 1

Prevalence of computed tomography features

	% Elbows	% Dogs
MCP fragmentation	15	22
MCP fissures	11	18
MCP sclerosis	2	4
MCP hypoattenuation	12	20
Abnormal MCP shape	42	48
Irregular radial incisure	14	20
Trochlear notch incongruity	4	4
Surface defect in humeral condyle (OCD, kissing lesion)	0	0
Fissure mid humeral condyle	8	14
Lucency mid humeral condyle	99	98
New bone lateral epicondylar crest	1	2
Osteophytes	60	68

Key: MCP = Medial coronoid process; OCD = osteochondritis dissecans.

one dog. In one elbow, the MCP was not fully included in the images resulting in 99 elbows available for analysis of this region of the joint.

Dogs had a mean age of 5 years 6 months (median 4 years 10 months; range 8 months – 14 years) and there was an even male-female distribution.

The prevalence of specific CT features is presented in ► Table 1. An area of indistinct hypoattenuation in the centre of the humeral condyle relative to the more marginal trabecular bone of the condyle (► Fig. 1) was seen in all but one humeral condyle. Excluding this feature, further CT abnormalities were identified in 69% dogs (65% elbows).

Abnormalities of the mid-sagittal humeral condyle included the presence of a hypoattenuating fissure with or without adjacent sclerosis (► Fig. 2). These changes were present in 14% dogs (8% elbows). Of the eight elbows with a fissure, only one did not also have sclerosis. All fissures were incomplete and had a mean length of 2.6 mm (range 1.0 – 4.8 mm). Fissures were either at the most distal (3 elbows) or most caudal (5 elbows) part of the condyle and all extended to the osseous surface of the condyle. Six of the eight elbows also had MCP disease. The mean age of dogs with a hypoattenuating fissure in the humeral condyle

(6y 2m) was not significantly different for those without a fissure (5y 4m, $p = 0.54$) and there was an equal male-female distribution.

Abnormalities of the MCP (fragmentation, fissures, sclerosis or hypoattenuation, abnormal shape, irregular radial incisure – ► Fig. 3) were present in 50% of the dogs (44% elbows).

In the 60% of the elbows with osteophytes, the mean and median osteophyte grades were 1.5 and 1.0 respectively (range 1 – 3).

Two dogs had humeroulnar incongruity of the trochlear notch and in both dogs this was bilateral. These four elbows all had MCP pathology (fragmentation and fissure fractures bilaterally in one dog, fissure fractures alone bilaterally in the other dog). One of these elbows also had an IOHC fissure.

The RUI measurements are listed in ► Table 2. There were not any significant differences between the normal group (36 elbows) and either the MCP disease group (44 elbows) or the IOHC group (8 elbows) for any RUI measurement although significance was approached for the dorsal plane RUI measurement halfway between the apex and base for the MCP disease group ($p = 0.07$).

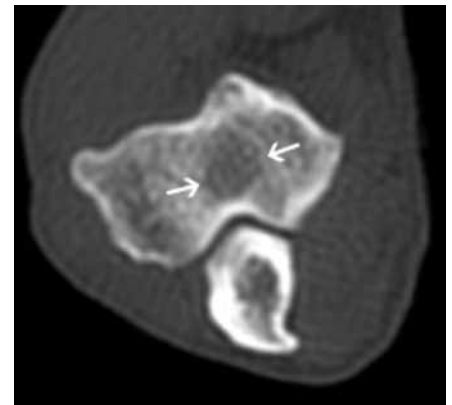


Fig. 1 Transverse computed tomographic image through the humeral condyle. Arrows indicate a diffuse area of hypoattenuation within the condyle (cranial top, medial right).

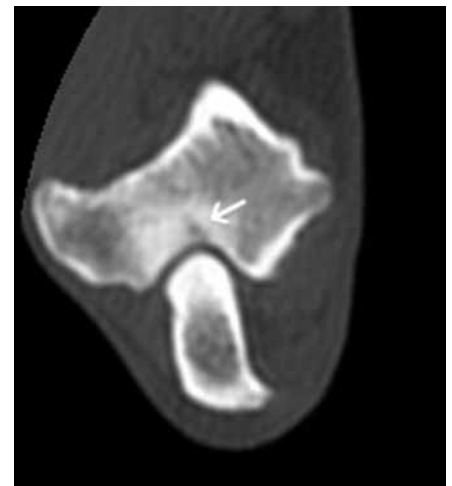


Fig. 2 Transverse computed tomographic image through the humeral condyle. Arrow indicates an incomplete fissure with adjacent hyperattenuation (cranial top, medial right).

Discussion

If the 50 dogs that were included in our study are representative of the general population of English Springer Spaniels then the prevalence of IOHC in the general population can be assumed to be around 14%. It is important to recognise however that the fissures we identified were all small and incomplete and not similar to the larger fissures we would expect to see in a dog with lameness associated with IOHC. Similar-sized incomplete fissures have been reported by other authors; in a study of the CT features of IOHC, 52% of the elbows

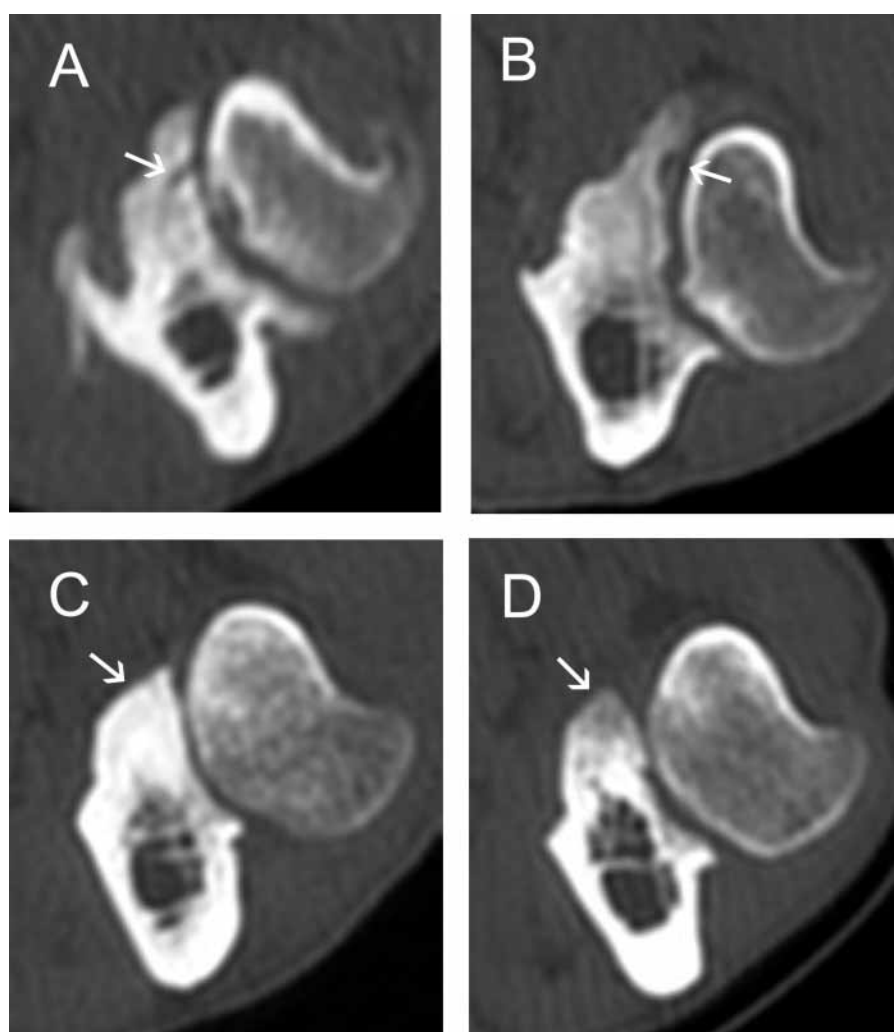


Fig. 3 Transverse computed tomographic images through the medial coronoid process (MCP) and radial head. Arrows indicate a fissure in the MCP (A), a MCP with an irregular radial incisure and abnormal shape (B), a hyperattenuating (sclerotic) MCP (C) and a hypoattenuating MCP (D). (All scans: cranial top, lateral right).

Table 2 Radioulnar incongruity (RUI) measurements (mm \pm standard deviation). Positive numbers indicate a relative decrease in size of the humeroulnar joint space compared to the humeroradial joint space (RUI = humeroradial measurement – humeroulnar measurement). p values for each comparison with normal elbows are shown in parentheses.

	Normal elbows	MCP disease	IOHC
Dorsal reconstruction: MCP apex	0.01 \pm 0.41	0.07 \pm 0.33 (0.54)	0.20 \pm 0.21 (0.25)
Dorsal reconstruction: MCP base	-0.13 \pm 0.14	-0.10 \pm 0.16 (0.42)	-0.06 \pm 0.21 (0.35)
Dorsal reconstruction: Halfway between MCP apex and base	-0.21 \pm 0.22	-0.10 \pm 0.26 (0.07)	-0.07 \pm 0.28 (0.19)
Sagittal reconstruction	0.01 \pm 0.10	0.04 \pm 0.14 (0.33)	-0.01 \pm 0.13 (0.86)

Key: MCP = medial coronoid process; IOHC = incomplete ossification of the humeral condyle. Data are shown as mean \pm the standard deviation.

had incomplete fissures with a median length of 4.8 mm (range, 0.9–8.2 mm) (8). Large incomplete fissures and complete fissures can be considered uncommon if our study population is representative of the general population. It may be of course that our inclusion criteria (which included no recent history of thoracic limb lameness) selected against dogs with larger fissures, if larger fissures are more likely to be associated with lameness. The propagation of a clinically-silent 3 mm long incomplete fissure to a complete fissure was associated with the development of lameness in one report (15). Clinical experience dictates that larger fissures can be an incidental finding during the investigation of dogs with contralateral IOHC or humeral condylar fracture, but it may be that larger IOHC fissures are only clinically silent for a limited period of time such that at any one time there is only a small proportion of non-lame dogs with larger fissures present in the population (10).

The aetiopathogenesis of IOHC remains unknown. It has been proposed that IOHC is a developmental abnormality due to a failure of fusion of secondary centres of ossification. However, in the cases identified in our study the humeral condyle appeared to have ossified normally apart from in the small areas where fissures were identified. An alternative scenario to incomplete fusion of the secondary centres of ossification is that the fissure represents a stress fracture of the humeral condyle. This suggestion is supported by the findings of CT-confirmed propagation of a partial IOHC fissure in an American Cocker Spaniel and the findings of a large CT-confirmed IOHC fissure in the condyle of an English Cocker Spaniel previously screened with CT and found not to have IOHC (15, 16). The presence of sclerotic bone adjacent to IOHC fissures also supports the stress fracture scenario; stress fractures also tend to be bordered by sclerotic bone (17). Stress fractures may occur with excessive stress on normal bone (fatigue fracture) or without abnormal stress in osteopaenic bone (insufficiency fracture) and either type could conceivably explain IOHC. Longitudinal studies are required to determine the true aetiopathogenesis of this condition.

Elbow joint incongruity would be a plausible factor in the pathogenesis of either a developmental failure of fusion or a stress fracture of the humeral condyle. Other authors have reported the finding of RUI in dogs with clinical IOHC although this was not something we identified in our study population, possibly because of the small number of IOHC cases available for statistical analysis (8). The role of RUI in relation to clinical cases with MCP disease is equally unclear with some authors reporting RUI only at the apex of the MCP and others reporting positive RUI at the base of the coronoid but no overall cumulative RUI (13, 18). Evaluating RUI can be problematic; different CT protocols have been described and CT measurement of RUI has been shown to be susceptible to changes in elbow positioning, particularly pronation and supination of the elbow (13, 14, 18, 19). We experienced difficulties in calculating RUI with one of the protocols previously described. We used a method described by Gemmill et al. to calculate RUI in the dorsal plane at the apex of the MCP (13). In that paper a second dorsal plane measurement is described, taken at the base of the MCP, using the most caudal part of the humeral trochlea as a reference point for locating the base. However, we found that the humero-ulnar joint space was frequently distorted in the obtained plane, making consistent measurements difficult. We therefore used a different method to identify the base of the MCP for dorsal plane joint space measurements (14).

A limitation of our study was that although all dogs were positioned similarly, different staff members were involved in positioning the dogs and elbow position was not precisely controlled; small variations in position are likely to have occurred and this may have influenced our RUI measurements. We did not identify a significant difference in RUI between normal elbows and elbows with MCP disease but this should be interpreted with caution; sample sizes were relatively small and a trend towards significance was identified at the mid-coronoid level.

Even if RUI is not present at the time of diagnosis of MCP disease, RUI has been proposed as a causal factor in the development of MCP disease if it is present at

some stage during skeletal development (20). If MCP disease is associated with RUI, either at the time of diagnosis or as a transient event during development, the high prevalence of MCP disease identified in our study population suggests that RUI could be common in English Springer Spaniels. RUI would be a plausible factor in the development of IOHC, and a high prevalence of RUI in English Springer Spaniels could be a factor in the pathogenesis of IOHC in this breed.

The high prevalence of MCP abnormalities and of periarticular osteophytes in our study was unexpected. Although MCP disease has been reported in English Springer Spaniels, as far as the authors are aware this is the first report documenting such a high prevalence (11). The high prevalence and the extent of the pathology in some cases is particularly surprising given that all dogs were reported to be free from thoracic limb lameness by their owners. It may well be that some of these dogs had a subtle lameness or had some elbow discomfort associated with these changes. Each dog had a full clinical examination prior to CT and no dogs were reported to have thoracic limb lameness or signs of elbow pain but not every case was examined by an orthopaedic surgeon or had a full orthopaedic examination.

We assessed the elbows in this study for a number of structural features. Some of these features are obvious (such as MCP fragmentation) and others can be more subtle. Other than fragmentation, other abnormal features of the MCP identified included fissure fractures, abnormal shape, irregular radial incisure, hyperattenuation and hypoattenuation (► Fig. 3). These features have been described by other authors as indicative of MCP pathology (12, 21). There is inherently some subjectivity to the assessment of some of the more subtle abnormalities. This was minimised in our study by the method in which these lesions were recorded; all elbows were evaluated in one sitting by three experienced evaluators and a consensus opinion achieved for the absence or presence of each abnormality. In the humeral condyle we noted a diffuse area of relative hypoattenuation in the centre of the condyle that was present in 99% of elbows (► Fig. 1). On the basis that this was almost ubiquitous in this popu-

lation we conclude that this can be considered a normal feature of the humerus in English Springer Spaniels. It is our experience that such an area of hypoattenuation is also a common feature of the humeral condyle in other breeds.

In conclusion, CT abnormalities of the elbow are common in English Springer spaniels and may not be associated with lameness. Pathology of the MCP is more common than IOHC.

Financial Support

Supported with a Clinical Research Grant from the British Veterinary Orthopaedic Association.

Conflict of interest

The authors have no conflicts of interest.

References

1. Denny HR. Condylar fractures of the humerus in the dog; a review of 133 cases. *J Small Anim Pract* 1983; 24:185–197.
2. Vannini R, Olmstead ML, Smeak DD. Humeral condylar fractures caused by minor trauma in 20 adult dogs. *J Am Anim Hosp Assoc* 1988; 24: 355–362.
3. Marcellin-Little DJ, DeYoung DJ, Ferris KK, et al. Incomplete ossification of the humeral condyle in spaniels. *Vet Surg* 1994; 23: 475–487.
4. Butterworth SJ, Innes JE. Incomplete humeral condylar fractures in the dog. *J Small Anim Pract* 2001; 42: 394–398.
5. Robin D, Marcellin-Little DJ. Incomplete ossification of the humeral condyle in two Labrador retrievers. *J Sm Anim Pract* 2001; 42: 231–234.
6. Rovesti GL, Fluckiger M, Margini A, et al. Fragmented coronoid process and incomplete ossification of the humeral condyle in a rottweiler. *Vet Surg* 1998; 27: 354–357.
7. Moores A. Humeral condylar fractures and incomplete ossification of the humeral condyle in dogs. *In Practice* 2006; 28: 391–397.
8. Carrera I, Hammond GJC, Sullivan M. Computed tomographic features of incomplete ossification of the canine humeral condyle. *Vet Surg* 2008; 37: 226–231.
9. Meyer-Lindenberg A, Heinen V, Fehr M, et al. Incomplete ossification of the humeral condyle as the cause of lameness in dogs. *Vet Comp Orthop Traumatol* 2002; 15: 187–194.
10. Martin RB, Crews L, Saveraid T, et al. Prevalence of incomplete ossification of the humeral condyle in the limb opposite humeral condylar fracture: 14 dogs. *Vet Comp Orthop Traumatol* 2010; 23: 168–172.
11. Groth AM, Benigni L, Moores AP, et al. Spectrum of computed tomographic findings in 58 canine elbows with fragmentation of the medial coronoid process. *J Small Anim Pract* 2009; 50: 15–22.

12. Moores AP, Benigni L, Lamb CR. Computed tomography versus arthroscopy for detection of elbow dysplasia lesions. *Vet Surg* 2008; 37: 390–398.
13. Gemmill TJ, Mellor DJ, Clements DN, et al. Evaluation of elbow incongruity using reconstructed CT in dogs suffering fragmented coronoid process. *J Small Anim Pract* 2005; 46: 327–333.
14. Gemmill TJ, Hammond G, Mellor D, et al. Use of reconstructed computed tomography for the assessment of joint spaces in the canine elbow. *J Small Anim Pract* 2006; 47: 66–74.
15. Witte PG, Bush MA, Scott HW. Propagation of a partial incomplete ossification of the humeral condyle in an American cocker spaniel. *J Sm Anim Pract* 2010; 51: 591–593.
16. Farrell M, Trevail T, Marshall W, et al. Computed tomographic documentation of the natural progression of humeral intracondylar fissure in a Cocker Spaniel. *Vet Surg* 2011; 40: 966–971.
17. Toal RL, Mitchell SK. Fracture Healing and Complications. In: Thrall DE, editor. *Textbook of Veterinary Diagnostic Radiology*. 4th edition. Philadelphia: W.B. Saunders Company; 2002. pg. 161–178.
18. Kramer A, Holsworth IG, Wisner ER, et al. Computed tomographic evaluation of canine radioulnar incongruence in vivo. *Vet Surg* 2006; 35: 24–29.
19. House MR, Marino DJ, Lesser ML. Effect of limb position on elbow congruity with CT evaluation. *Vet Surg* 2009; 38: 154–160.
20. Gemmill TJ, Clements DN. Fragmented coronoid process in the dog: is there a role for incongruency. *J Sm Anim Pract* 2007; 48: 361–368.
21. Cook CR, Cook JL. Diagnostic imaging of canine elbow dysplasia: a review. *Vet Surg* 2009; 38: 144–153.