

Minimally invasive plate osteosynthesis: Applications and techniques in dogs and cats

C.C. Hudson; A. Pozzi; D.D. Lewis

Department of Small Animal Clinical Sciences, University of Florida, Gainesville, Florida, USA

Keywords

Minimally invasive plate osteosynthesis, biological osteosynthesis

Summary

Bone plating has been used as a method of fracture management for many years. Recently, a trend toward the use of fracture fixation techniques which preserve the local fracture environment, known as biological osteosynthesis, has evolved. This trend has resulted in the development of a less traumatic method of bone plating referred to as minimally invasive plate osteosynthesis (MIPO), or percutaneous plating. During MIPO fracture stabilisation, plates are inserted through short

incisions and a communicating epiperiosteal tunnel. Typically, bone plates applied in this fashion have a bridging function. Promising outcomes have been reported in human patients undergoing MIPO fracture stabilisation, and limited reports of the use of this technique in dogs and cats have yielded positive results as well. Careful case selection, pre-operative planning, and appropriate instrumentation are necessary when performing the technique. Rapid time to union, low complication rates and good return to function have been noted in human patients. Additional research is needed to define selection criteria and outline the definitive benefits of MIPO in dogs and cats.

Correspondence to

Dr. Antonio Pozzi, DMV, MS, Diplomate ACVS
Department of Small Animal Clinical Sciences
College of Veterinary Medicine
University of Florida
Gainesville, FL 32610
USA
Phone: +1 352 392 2226
Fax: +1 352 392 6125
E-mail: Pozzi@vetmed.ufl.edu

Vet Comp Orthop Traumatol 2009; 22: 175–182

doi:10.3415/VCOT-08-06-0050

Received: June 14, 2008

Accepted: February 2, 2009

Prepublished online: April 3, 2009

Introduction and history

Bone plating has been used as a method of fracture management since the late 1800's (1, 2). Initial attempts at bone plating frequently resulted in infection, malunion or nonunion, or a poor return to function (2, 3). In 1958, a group of Swiss orthopaedic surgeons formed the 'Arbeitsgemeinschaft für Osteosynthesefragen' (AO), also known as the 'Association for the Study of Internal Fixation' (3, 4). Their research and techniques emphasised a rapid return to pain-free functionality following fracture repair (5). The principles for fracture management developed by the AO group eventually helped standardize the protocols

for osteosynthesis amongst the medical community (3). Widespread application of the AO principles resulted in a paradigm shift with respect to the goals and techniques of osteosynthesis; the group's ongoing research has continued to define the *standard of care* for fracture management (2, 3). Initially, the AO principles recommended that precise anatomic fracture reconstruction be performed prior to plating (2). Anatomic reduction generally required extensive surgical exposure and manipulation of the fractured bone to facilitate precise reconstruction of the fracture fragments. The reconstructed fracture was often stabilised with interfragmentary screws or circumferential cerclage

wires prior to application of a bone plate (3). In order to achieve rigid fixation, plates were precisely contoured and tightly compressed against the periosteal surface of the bone. Rigid fixation and interfragmentary compression promoted direct bone healing with minimal callus formation (1, 2, 6).

Continued research in the area of fracture healing led to a change in the philosophies and goals of fracture osteosynthesis (7, 8). Modifications in plate design were developed to improve the biology of the implant-bone interface (2, 9). The limited contact dynamic compression plate (LC-DCP) was similar in design to the standard dynamic compression plate (DCP), but the LC-DCP had a scalloped contact surface. The LC-DCP was developed to mitigate the plate's interference with the bone's cortical circulation (2). The design of the LC-DCP subsequently led to the development of the point contact fixator (PC-Fix), which combined a scalloped contact surface with conical screw holes that allowed the screw heads to be effectively locked into the plate holes. The PC-Fix provided stable fixation without compressive bone-plate contact (2, 10). Most recently, the locking compression plate (LCP) has been developed. The LCP has a combination-screw hole which can function as either a locking hole or a compression hole. When the locking screw function is employed, the LCP functions as an internal fixator and the plate does not need to contact the cortical surface of the engaged bone segments in order to provide stable fixation (9, 11–14).

Recent advancements in fracture management within the human medical field have focused on minimally invasive fracture stabilisation techniques (8, 15). Invasive open surgical approaches necessary for anatomic fracture reconstruction disrupt the fracture haematoma as well as the regional extraosseous blood supply (8, 16, 17). This iatrogenic trauma can retard the rate of new bone formation and devitalize bone fragments, which

potentially may have remained viable had the fracture site not been disturbed (18–20). An understanding of the benefits of preserving the fracture haematoma and local blood supply has led to the development of *the principles of biological osteosynthesis* as a technique for fracture management (6–8, 21).

Principles of biological osteosynthesis

The principles of biological osteosynthesis were developed in order to maximize healing potential by balancing biology and mechanics in the treatment of fractures (3, 8). The basic principles of biological osteosynthesis include:

1. Minimize iatrogenic soft tissue disruption.
2. Utilize indirect fracture reduction techniques.
3. Provide appropriate stable fixation.
4. Promote the early return to limb function (5, 6).

These principles are based on the need for preservation of blood supply by minimizing exposure and disruption of the fracture site. The fracture is not necessarily reconstructed anatomically. Instead, the major fracture segments are aligned in a functional position without surgical exposure using indirect reduction, or by using an *open but do not touch* technique if exposure is necessary (21). This method mitigates disturbance of the fracture haematoma and the periosteal soft tissues (22). Plates, external skeletal fixators or interlocking nails are used to maintain alignment of the major fracture segments. Fracture union occurs by indirect bone healing with formation of a bridging callus followed by osseous remodelling (23, 24). One beneficial result of biologic osteosynthesis is reduced operative time (25). Reduced operative time has been shown to decrease the risk of infection (26); fractures that heal without infection are less likely to be further complicated by fixation failure (15), the need for bone grafting (27, 28) or delayed union (25, 29, 30).

Fracture stabilisation using an external skeletal fixator is a technique that has been utilised extensively in veterinary medicine for over 70 years (31). External skeletal fixation is often applied in a manner consistent with the

principles of biological osteosynthesis. When closed reduction techniques are used, the fracture site is not exposed and the fixation elements are applied through insertion incisions remote from the fracture site (6, 21, 23, 32). During the post-operative convalescent period, morbidity arising from pin tract infection and associated pin loosening is common with external skeletal fixators (33). Methods of internal fixation, which adhere to the principles of biological osteosynthesis, could circumvent many of the post-operative complications that are inherent in external skeletal fixation. A new method of bone plating has evolved that allows a plate to be applied through small incisions made remote from the fracture site. This technique conforms to the principles of biological osteosynthesis since the fracture site is not exposed and only minimally disturbed. The technique has been termed minimally invasive percutaneous plate osteosynthesis (MIPO), and has also been referred to as percutaneous plating (1, 34, 35) (► Fig. 1).

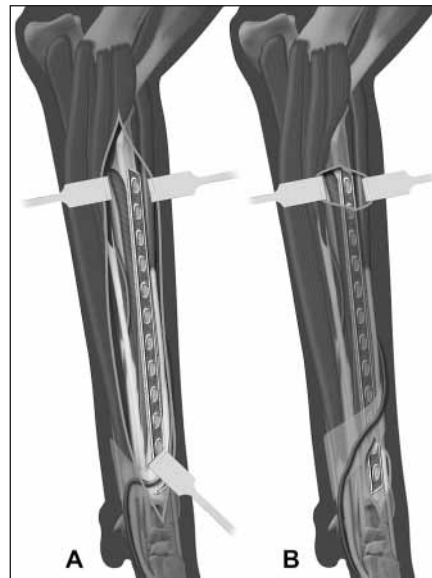


Fig. 1 Schematic illustration of open reduction and internal fixation versus minimally invasive plate osteosynthesis of a radial fracture. A) Extensive approach typically utilised for open plating of a diaphyseal radial fracture; B) minimally invasive plate osteosynthesis stabilisation of a radial fracture. The plate has been inserted in the epiperiosteal tunnel via the short insertion incisions resulting in minimal soft tissue dissection.

Overview and principles of minimally invasive plate osteosynthesis

Percutaneous plating involves the application of a bone plate, typically in a bridging fashion, without making an extensive surgical approach to expose the fracture site (5, 36). The bone segments are reduced using indirect reduction techniques (37). Small plate insertion incisions are made at each end of the fractured bone and an epiperiosteal tunnel connecting the incisions is created. The plate is inserted through one of the insertion incisions and slid through the tunnel along the periosteal surface of the bone, spanning the fracture site. Screws are applied at the proximal and distal ends of the plate through the insertion incisions, or if necessary, through additional stab incisions.

As with most techniques, there are both advantages and disadvantages associated with MIPO. Operative time is reduced compared to anatomic reconstruction once familiarity with the procedure is developed (38, 39). Minimally invasive procedures carry a lower risk of bacterial infection in comparison to open reconstruction procedures due to shorter duration of surgery, limited iatrogenic soft tissue trauma, and decreased potential for intra-operative contamination of the fracture site (5, 21, 26, 40). The preservation of the fracture haematoma during surgery may contribute to an increased rate of callus formation. Mizuno et al demonstrated in a rat model that the fracture haematoma possesses inherent osteogenic properties (20). Cadaveric studies showed that perforating arteries are preserved to a much greater extent when using MIPO techniques in comparison to conventional plating, resulting in conservation of the periosteal blood supply, which in turn may contribute to an increased rate of fracture healing (16, 17, 41). The results of these studies, however, should be interpreted cautiously as none of these studies evaluated periosteal blood flow under *in vivo* conditions. Fractures stabilised with MIPO should heal in a similar manner to fractures stabilised with external skeletal fixation applied in a closed fashion (18), but the former would require less patient and fixator care in the post-operative convalescence period (42, 43). There are several studies that provide

support for the hypothesis that the healing of fractures managed by MIPO is more rapid than with conventional plating techniques. In a femoral fracture model study performed in sheep, biological plating techniques yielded shorter times to union than fractures stabilised with anatomic reconstruction and plating (15). Furthermore, a retrospective study evaluating fracture repairs in 35 dogs found that bridging plate fixation resulted in a significantly shorter time to union than anatomic reconstruction and plate fixation (25). A clinical trial in human patients with displaced intra-articular radial fractures demonstrated that indirect reduction and percutaneous plate osteosynthesis resulted in a more rapid return to function and a better functional outcome than management of fractures with open reduction and internal fixation (44). Also, pain may be reduced during the post-operative period compared to traditional plating because of the limited skin incisions and manipulation of bone segments required during MIPO (5).

There are some obvious disadvantages associated with MIPO. The technique can be technically challenging to learn and apply (27, 45). Minimally invasive plate osteosynthesis may be less suitable for simple and articular fractures that require precise anatomic reduction and interfragmentary compression (3, 5). Minimally invasive plate osteosynthesis does not allow direct observation of the fracture fragments; therefore, access to intra-operative fluoroscopy or radiography greatly facilitates the surgical procedure. Unfortunately, the use of fluoroscopy has greatly increased the amount of radiation exposure for the surgery team and the patient (36).

Case selection

Appropriate case selection is crucial to the success of MIPO. As with any technique, not all fractures are amenable to percutaneous plate stabilisation. Although MIPO is most applicable to comminuted diaphyseal or metaphyseal fractures that may not be amenable to anatomic reduction, the technique can be utilised in some simple transverse fractures (5, 36, 45, 46). Plates are typically applied in a bridging fashion to stabilize comminuted fractures, dissipating strain over the comminuted segment. (5, 8, 47). The en-

vironment of relative stability provided by bridge plating results in fracture healing by secondary bone healing (18, 23, 25).

Although the MIPO technique has been applied to proximal limb fractures in human patients, we have found that femoral and humeral fractures are typically more challenging to reduce using indirect techniques than antebrachial and crural fractures in small animals. Femoral and humeral fractures in dogs and cats may be more amenable to MIPO if applied in combination with an intramedullary pin, fracture distractor or traction table to achieve reduction and alignment (22, 48). In human patients, MIPO has been demonstrated to be a successful method of fracture osteosynthesis in both humeral and femoral fractures (27, 39, 49–54). Minimally invasive plate osteosynthesis has been utilised to stabilize comminuted tibial fractures in both human patients (37, 55, 56) and dogs (38, 57). In our experience, MIPO can be readily applied to radial and tibial fractures that have been indirectly reduced using a temporary external skeletal fixator. Minimally invasive plate osteosynthesis is well-suited to the stabilisation of diaphyseal long-bone fractures as there is usually a sufficient length of bone proximal and distal to the fracture to allow for appropriate plate application (57). Metaphyseal and epiphyseal fractures are commonly repaired using MIPO in human patients; but the decision to utilize MIPO in dogs with fractures in these locations must be made on a *case by case* basis and is dependent upon the bone affected and the availability of specialty plates (45, 58, 59). A number of specialty plates are available for use in human patients, and these plates allow excellent implant purchase in short juxta-articular fracture segments (59). Articular fractures are rarely amenable to MIPO. The need for anatomic reduction and rigid fixation generally necessitates open techniques when articular fractures require plate stabilisation (3). If MIPO is attempted in fractures requiring anatomic reduction, then the use of intra-operative fluoroscopy or arthroscopy during reduction is highly recommended (22, 60). A final consideration is the specific anatomy in the region of the fracture and the intended surgical approach. If major neuro-vascular structures are situated in proximity to the fracture site or intended surgical approach, then a MIPO technique may not be the best

option as it does not allow for adequate visualization and protection of major vessels or nerves (36). Careful attention to these guidelines of case selection is important since application of any construct in the wrong setting using MIPO may greatly increase the chance of complication or failure.

Pre-operative planning

Appropriate pre-operative planning is an essential component of the MIPO technique. Well-positioned, orthogonal radiographic views of both the fractured and the contralateral intact limb segments are required to properly plan the procedure. Pre-contouring of an appropriate length plate can be performed utilizing images of the contralateral limb segment if these images are available (38). Implant selection should be based on fracture pattern and location as well as the animal's size and weight. Schmokel et al recommend the use of a long plate in MIPO applications in order to dissipate the stress on the construct (57). Longer plates utilizing a limited number of screws positioned near the plate ends have been shown to sustain greater loads before failure than shorter plates with a screw placed in each hole in the plate (61, 62). The use of longer plates applied without the placement of screws in some of the more centrally located plate holes has also been advocated when performing elastic plating in young dogs (63, 64). We have had success utilizing DCP, LC-DCP, or LCP systems for MIPO procedures. Newer plating systems utilizing a locking plate-screw interface, such as the LCP, lend themselves particularly well to MIPO because they provide angular stability, which increases the load-carrying capacity of the construct (11,12,13). The angular stability results from the threaded screw heads being locked into the threaded plate holes, thus forming a fixed-angle construct. For MIPO application, another important advantage of locking plates is the minimal contouring required for application of the plate in contrast to traditional plates, which require optimal contouring in order to maintain reduction of the fracture. Locking plates act as internal fixators, and therefore do not displace the fracture segments during screw tightening regardless of the precision of contouring (12, 13, 65–68)

Fracture reduction

Indirect reduction techniques are generally utilised when performing MIPO fracture stabilisation. The fractured limb segment is aligned and original length is restored. The intermediate fracture fragments are left undisturbed in the soft tissue envelope (6, 22, 23). The vascularised fragments will be incorporated into the fracture callus (22, 69). Regardless of the technique used, any reduction manoeuvre should be as atraumatic as possible for the soft tissues and periosteum in order to preserve the existing blood supply (70). Irrespective of the fracture configuration, the aim of the reduction is to restore length and alignment so that the joints proximal and distal to the fracture are in the correct orientation (22). Indirect reduction means that fracture segments are manipulated indirectly by applying corrective force at a distance from the fracture, by distraction or other means, without exposing the fracture (22, 58). If correctly applied, indirect reduction techniques will induce minimal iatrogenic damage to tissues which have already been traumatised by the fracture (22).

The hanging-limb technique, which involves suspending the affected limb and allowing the animal's body weight to assist in distraction and alignment of the fracture, is a commonly recommended method of indirect reduction (6, 21, 22). Reduction forceps can be applied through stab incisions to grip the proximal and distal segments and manipulate them into alignment (56). This method is most successful in distal limb fractures where

the nominal muscle mass allows more accurate palpation techniques (47).

A circular external fixator with fixation wires engaging both the proximal and distal fracture segments can be used to distract the fracture, restoring length and alignment. We routinely use a two-ring construct to distract the major fracture segments and to obtain functional alignment prior to plate insertion. As an alternative, the fracture distractor is an adjustable unilateral fixator which can be particularly useful for reducing humeral and femoral fractures (22).

An intramedullary Steinmann pin can be used to assist with reduction and alignment of the fracture. The tip of the pin is blunted before the pin is introduced into the distal fracture segment, allowing enough force to be applied to achieve distraction of the proximal and distal fracture segments (22). Distraction by this method is very effective at stretching out contracted muscles and restoring the fractured bone to original length (22). The pin can be left in place to function as a plate-rod construct, or it can be removed once the plate has been secured to the major bone segments (6, 71, 72). Another simple reduction method that we occasionally utilize consists of a pre-contoured plate applied with non-locking screws. Applying a properly contoured plate to the displaced, major fracture segments inherently reduces the fracture. This technique corrects small displacements and angulation while maintaining stability as the reduction occurs (36, 69).

Specialised surgical tables are made that allow traction to be consistently applied to in-

dividual appendicular long bones. Rovesti et al have described appropriate patient positioning, as well as the anchorage points for application of traction to the humerus, femur, radius and ulna, and tibia in dogs (73). Traction tables are routinely used in human patients for fracture reduction and the results of a clinical study performed in 21 dogs suggests that this technique also has good success in dogs (48).

Surgical approach

The surgical approach should be chosen based on knowledge of regional anatomy such that the approach does not compromise major neurovascular structures (36, 53). The skin incisions are made over the anticipated proximal and distal locations of the plate (52, 74). Soft-tissue incisions are generally two to four cm long and should be large enough to expose the underlying bone and permit the introduction and subsequent manipulation of the plate on the bone surface (5, 51). Once the two plate insertion incisions are made, an epiperiosteal soft tissue tunnel is created using blunt dissection. A pair of long, blunt scissors or a long periosteal elevator is used to create the soft tissue tunnel immediately adjacent to the periosteal surface of the bone (36, 38, 57). The periosteum is deliberately not elevated and care should be taken to minimize iatrogenic trauma to the fracture site (5, 36). The completed tunnel should lie directly superficial to the periosteal surface of the underlying bone, communicating with the two insertion incisions (56, 75).

Plate application

The plate is inserted through one of these incisions and slid through the soft tissue tunnel adjacent to the surface of the bone, and over the fracture site until the end of the plate is visible in the second incision (38, 57, 75) (► Fig. 2). If available, fluoroscopy should be used to confirm that the plate is properly contoured and positioned on the bone (36, 45, 51). If necessary the plate can be removed and re-contoured (59). Precise contouring and positioning of the plate becomes less critical if a locking plate is used (5, 12). Once the plate is fitted to the bone, screws are placed.



Fig. 2 Minimally invasive plate osteosynthesis stabilisation of a comminuted femoral fracture in a dog. A locking compression plate has been inserted from distal-to-proximal, sliding the plate through the epiperiosteal tunnel. The locking compression plate's drill guide can be utilised as a handle to facilitate insertion and positioning of the plate.

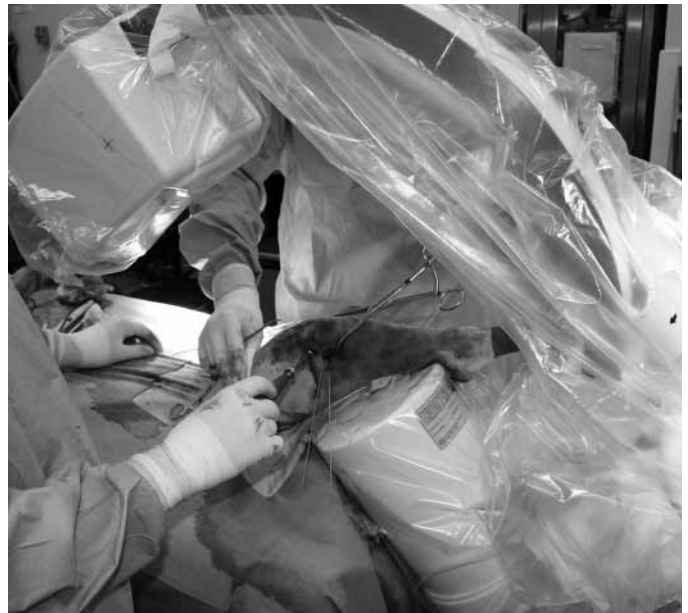Typically one or more screws are placed to secure either the proximal or distal segment and then the alignment of the limb segment is re-assessed (52, 56). Screws can then be placed through the remaining accessible holes via both the proximal and distal insertion incisions (52, 56). Screws can be placed through inaccessible plate holes by making stab incisions through the overlying soft tissue and using fluoroscopy to guide screw placement (55, 59, 75) (► Fig. 3). Filling all the holes in the plate with screws is not necessary when applying long plates. A study by Weiss et al using an ulna fracture gap model found that yield strength of the construct was greater with the use of a 10-hole plate applied with four screws, than an eight-hole plate with six screws (61). Gautier and Sommer recommended the use of two or three bicortical screws per major fracture segment, with a total plate-screw density (quotient of the number of screws utilised divided by the total number of plate holes) of 0.4 to 0.5 for MIPO applications using locking plates in human patients. In addition the authors recommended that peripheral screws be inserted at the ends of the plate and centrally located screws be inserted adjacent to the fracture site to maximize working leverage and minimize pull-out forces acting on the screws (11). The optimal number of screw-cortical interfaces per fracture segment in fractures treated with MIPO has not been definitively determined for dogs and cats. Previous studies have reported that successful outcomes in dogs and cats were achieved when two to four bicortical screws per major fracture segment were utilised (38, 57). Closure of soft tissues is routine, and post-operative radiographs are obtained to confirm proper limb alignment, plate placement, and screw position (38, 52, 57).

Post-operative care

Post-operative treatment following surgery in human patients typically consists of passive range of motion exercises started within the first few days following surgery (27, 74, 75). In human patients, the time at which partial weight-bearing on the injured limb is permitted by surgeons varies from immediately to eight weeks following the surgery (27, 74, 76). Schmokel et al recommended applying a

Fig. 3

Fluoroscopic guided screw insertion during fixation of an intra-articular tibial plateau fracture utilizing minimally invasive plate osteosynthesis. Intra-operative fluoroscopy is invaluable in assessing reduction and plate positioning when performing minimally invasive plate osteosynthesis procedures.



modified Robert Jones bandage for several days and limiting exercise to indoor confinement with leash walks for six to 10 weeks in dogs that have had fractures stabilised using the MIPO technique (38, 57). Our approach to post-operative care of dogs and cats following MIPO typically involves application of a modified Robert Jones bandage after surgery to help reduce swelling in the immediate post-operative period. The bandage is usually removed when the animal is discharged from the hospital, one to three days following surgery. Activity is restricted to cage confinement with leash walks of increasing duration over the first six weeks. Range of motion exercises are performed two to three times daily during the convalescent period. Recheck radiographs are obtained at one, two and three months post-operatively. Increased patient activity is allowed once evidence of fracture healing is noted radiographically. Once radiographic healing is complete, the plate may be removed based on surgeon preference and patient tolerance of the implant (38, 57).

Outcome

Limited information has been published regarding post-operative outcomes and complications in dogs and cats following MIPO. In 2003, the outcome of MIPO fixation of ti-

bial fractures in two dogs was reported (57). The fractures in both dogs obtained radiographic union at five and 11 weeks, without any complications (57). A subsequent publication in 2007 reported return to full limb use after two to three months in six dogs and four cats with fractures treated using MIPO (38). The only complication noted was proximal screw loosening in one case, which progressed to union without intervention (38). Our own early clinical experience with MIPO procedures includes 16 dogs. We noted substantial callus formation when the first post-operative radiographs were obtained (mean 5.5 weeks) after fracture fixation with a mean time to radiographic union being 16.7 (range six to 23) weeks. All dogs had standardised recheck examinations at one, two and three months as a minimum (46). Overall our results have been very positive (► Fig. 4), although implant failure occurred in one dog.

There are numerous reports regarding outcomes of MIPO procedures in human patients. Lau et al in 2007 reported the outcome of 48 patients treated with MIPO at the University of Hong Kong. The mean time to full weight-bearing in their patients was 9.4 weeks and the mean time to radiographic union was 18.7 weeks. The incidence of late infection was 15%, although the authors did not find that there was any correlation between infection and time to union (77). Other human case series studies of MIPO for tibial fractures have reported times

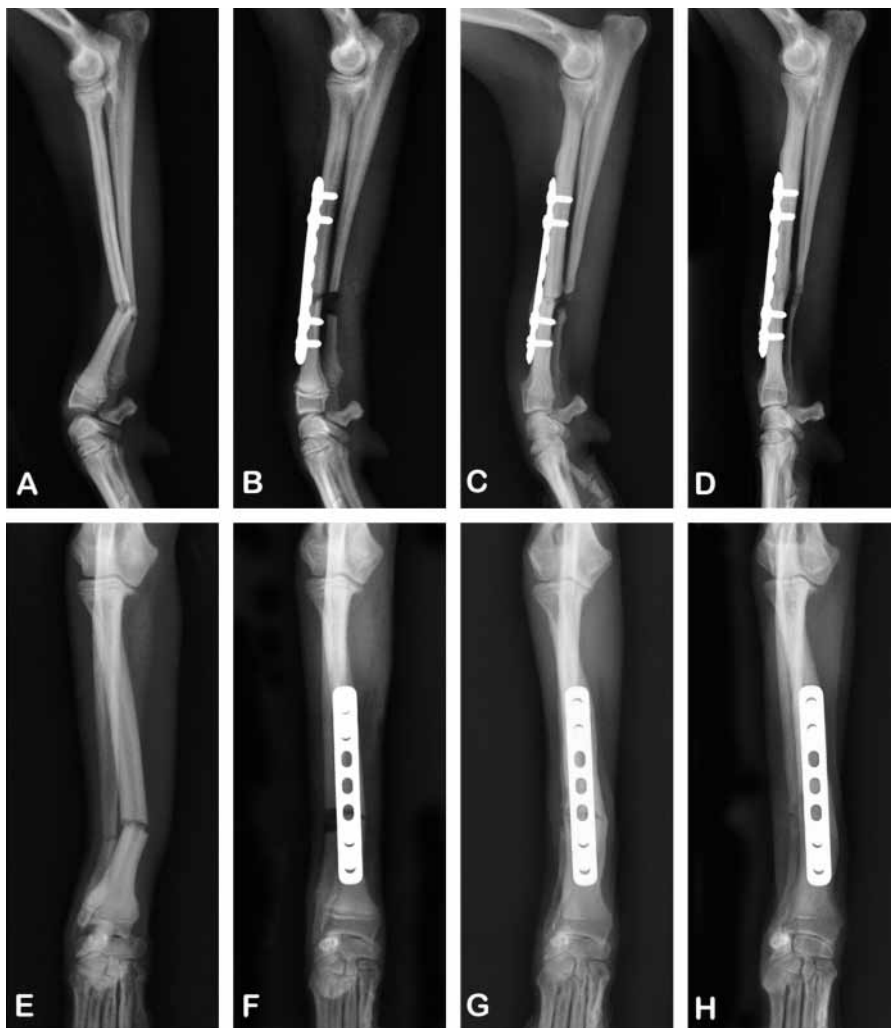

Fig. 4 Pre-operative, post-operative and follow-up radiographs of a radial fracture repaired with minimally invasive plate osteosynthesis. A seven-hole, 2.0 mm limited contact dynamic compression plate has been applied on the dorsal surface of the radius. A) and E) Pre-operative medio-lateral and cranio-caudal radiographs; B) and F) immediate post-operative medio-lateral and cranio-caudal radiographs; C) and G) four-week follow-up medio-lateral and cranio-caudal radiographs; D) and H) eight-week follow-up medio-lateral and cranio-caudal radiographs.

to full weight-bearing ranging from six to 22 weeks and times to union ranging from eight to 29 weeks (eight to 42 weeks including delayed unions) (55, 56, 76). Post-operative complications occurred infrequently and were similar to those seen with other internal fixation techniques, including superficial or deep infection, screw loosening or breakage, implant failure, delayed union, malunion, nonunion, and re-operation (28, 37, 38, 50, 55, 59).

Conclusion

MIPO is a modality which results in a relatively stable fracture construct while preserving a biologic environment that facilitates rapid bone healing. While MIPO is most applicable to comminuted fractures of long bones, the technique is also applicable to selected simple fractures (46). The reported outcomes of MIPO procedures have been favourable, with rapid stabilisation of the fracture site by bridging callus, progressing to complete union (38, 57, 77). This technique has gained rapid acceptance for fracture

fixation in human patients over the past several years, with numerous case reports supporting the use of MIPO techniques in tibial, femoral and humeral fractures (34, 39, 52, 53, 56, 75, 76). Recently, veterinarians have also begun performing MIPO procedures in dogs and cats (38, 57). Despite the potential advantages of minimally invasive fracture fixation, there is still a lack of randomised prospective studies comparing MIPO to conventional open reduction and internal fixation technique in people and animals. In order to substantiate MIPO for use in dogs and cats, objective clinical trials with validated outcome measures need to be performed. It is our hope that this review will help spark interest in the application of MIPO in small animal practice and incite further research in this new and exciting field of biologic plate osteosynthesis.

References

1. Miclau T, Martin RE. The evolution of modern plate osteosynthesis. *Injury* 1997; 28 (Suppl 1): A3–6.
2. Schutz M, Sudkamp NP. Revolution in plate osteosynthesis: new internal fixator systems. *J Orthop Sci* 2003; 8: 252–258.
3. Schatzker J. Changes in the AO/ASIF principles and methods. *Injury* 1995; 26 (Suppl 2): B51–B56.
4. Transforming surgery - changing lives: history [document on internet]. AO Foundation 2008 [updated 2008; cited 2008 May 20]. Davos Platz, Switzerland. Available from: <http://www.aofoundation.org/portal/wps/portal/Home>.
5. Wagner M, Frigg R. AO manual of fracture management, internal fixators: concepts and cases using LCP and LISS. Clavadelstrasse: AO Publishing; 2006: 1–57.
6. Palmer RH. Biological osteosynthesis. *Vet Clin North Am Small Anim Pract* 1999; 29: 1171–1185, vii.
7. Perren SM. Evolution of the internal fixation of long bone fractures. The scientific basis of biological internal fixation: choosing a new balance between stability and biology. *J Bone Joint Surg Br* 2002; 84: 1093–1110.
8. Field JR, Tornkvist H. Biological fracture fixation: a perspective. *Vet Comp Orthop Traumatol* 2001; 14: 169–178.
9. Perren SM. Backgrounds of the technology of internal fixators. *Injury* 2003; 34 Suppl 2: B1–3.
10. Tepic S, Perren SM. The biomechanics of the PC-Fix internal fixator. *Injury* 1995; 26 (Suppl 2): B5–10.
11. Gautier E, Sommer C. Guidelines for the clinical application of the LCP. *Injury* 2003; 34 (Suppl 2): B63–76.
12. Wagner M. General principles for the clinical use of the LCP. *Injury* 2003; 34 (Suppl 2): B31–42.
13. Egol KA, Kubiak EN, Fulkerson E, et al. Biomechanics of locked plates and screws. *J Orthop Trauma* 2004; 18: 488–493.

14. Ahmad M, Nanda R, Bajwa AS, et al. Biomechanical testing of the locking compression plate: When does the distance between bone and implant significantly reduce construct stability? *Injury* 2007; 38: 358–364.
15. Baumgaertel F, Buhl M, Rahn BA. Fracture healing in biological plate osteosynthesis. *Injury* 1998; 29 Suppl 3: C3–6.
16. Farouk O, Krettek C, Miclau T, et al. Effects of percutaneous and conventional plating techniques on the blood supply to the femur. *Arch Orthop Trauma Surg* 1998; 117: 438–441.
17. Borrelli J, Prickett W, Song E, et al. Extraosseous blood supply of the tibia and the effects of different plating techniques: a human cadaveric study. *J Orthop Trauma* 2002; 16: 691–695.
18. Claes L, Heitemeyer U, Krischak G, et al. Fixation technique influences osteogenesis of comminuted fractures. *Clin Orthop Relat Res* 1999; 365: 221–229.
19. O'Sullivan ME, Chao EY, Kelly PJ. The effects of fixation on fracture-healing. *J Bone Joint Surg Am* 1989; 71: 306–310.
20. Mizuno K, Mineo K, Tachibana T, et al. The osteogenic potential of fracture hematoma. Subperiosteal and intramuscular transplantation of the hematoma. *J Bone Joint Surg Br* 1990; 72: 822–829.
21. Aron DN, Palmer RH, Johnson AL. Biologic strategies and a balanced concept for repair of highly comminuted long bone fractures. *Comp Cont Edu Small Anim* 1995; 17: 35–47.
22. Johnson AL. Current concepts in fracture reduction. *Vet Comp Orthop Traumatol* 2003; 16: 59–66.
23. Johnson AL, Egger EL, Eurell JC, et al. Biomechanics and biology of fracture healing with external skeletal fixation. *Comp Cont Edu Small Anim* 1998; 20: 487–501.
24. Palmer RH, Hulse DA, Hyman WA, et al. Principles of bone healing and biomechanics of external skeletal fixation. *Vet Clin North Am Small Anim Pract* 1992; 22: 45–68.
25. Johnson AL, Smith CW, Schaeffer DJ. Fragment reconstruction and bone plate fixation versus bridging plate fixation for treating highly comminuted femoral fractures in dogs: 35 cases (1987–1997). *J Am Vet Med Assoc* 1998; 213: 1157–1161.
26. Eugster S, Schawalder P, Gaschen F, et al. A prospective study of postoperative surgical site infections in dogs and cats. *Vet Surg* 2004; 33: 542–550.
27. Krettek C, Schandelmaier P, Miclau T, et al. Minimally invasive percutaneous plate osteosynthesis (MIPO) using the DCS in proximal and distal femoral fractures. *Injury* 1997; 28 Suppl 1: A20–30.
28. Papakostidis C, Grotz MR, Papadokostakis G, et al. Femoral biologic plate fixation. *Clin Orthop Relat Res* 2006; 450: 193–202.
29. Rozbruch SR, Muller U, Gautier E, et al. The evolution of femoral shaft plating technique. *Clin Orthop Relat Res* 1998; 354: 195–208.
30. Horstman CL, Beale BS, Conzemius MG, et al. Biological osteosynthesis versus traditional anatomic reconstruction of 20 long-bone fractures using an interlocking nail: 1994–2001. *Vet Surg* 2004; 33: 232–237.
31. Pettit GD. History of external skeletal fixation. *Vet Clin North Am Small Anim Pract* 1992; 22: 1–10.
32. Johnson AL, Seitz SE, Smith CW, et al. Closed reduction and type-II external fixation of comminuted fractures of the radius and tibia in dogs: 23 cases (1990–1994). *J Am Vet Med Assoc* 1996; 209: 1445–1448.
33. Harari J. Complications of external skeletal fixation. *Vet Clin North Am Small Anim Pract* 1992; 22: 99–107.
34. Tong G, Bavonratanevech S. AO manual of fracture management: minimally invasive plate osteosynthesis (MIPO). Clavadelstrasse: AO Publishing; 2007: 3–7.
35. Krettek C, Muller M, Miclau T. Evolution of minimally invasive plate osteosynthesis (MIPO) in the femur. *Injury* 2001; 32 (Suppl 3): C14–23.
36. Ruedi TP, Buckley R, Moran CG. AO principles of fracture management, volume 1-Principles. Second ed. Clavadelstrasse: AO Publishing; 2007: 199–210.
37. Borg T, Larsson S, Lindsjo U. Percutaneous plating of distal tibial fractures. Preliminary results in 21 patients. *Injury* 2004; 35: 608–614.
38. Schmokel HG, Stein S, Radke H, et al. Treatment of tibial fractures with plates using minimally invasive percutaneous osteosynthesis in dogs and cats. *J Small Anim Pract* 2007; 48: 157–160.
39. Henry SL. Supracondylar femur fractures treated percutaneously. *Clin Orthop Relat Res* 2000; 375: 51–59.
40. Arens S, Kraft C, Schlegel U, et al. Susceptibility to local infection in biological internal fixation. Experimental study of open vs minimally invasive plate osteosynthesis in rabbits. *Arch Orthop Trauma Surg* 1999; 119: 82–85.
41. Farouk O, Krettek C, Miclau T, et al. Minimally invasive plate osteosynthesis: Does percutaneous plating disrupt femoral blood supply less than the traditional technique? *J Orthop Trauma* 1999; 13: 401–406.
42. Aron DN, Dewey CW. Application and postoperative management of external skeletal fixators. *Vet Clin North Am Small Anim Pract* 1992; 22: 69–97.
43. Marcellin-Little DJ. Fracture treatment with circular external fixation. *Vet Clin North Am Small Anim Pract* 1999; 29: 1153–1170.
44. Kreder HJ, Hanel DP, Agel J, et al. Indirect reduction and percutaneous fixation versus open reduction and internal fixation for displaced intra-articular fractures of the distal radius: a randomised, controlled trial. *J Bone Joint Surg Br* 2005; 87: 829–836.
45. Collinge CA, Sanders RW. Percutaneous plating in the lower extremity. *J Am Acad Orthop Surg* 2000; 8: 211–216.
46. Pozzi A, Hudson CC, Lewis DD. Minimally invasive plate osteosynthesis: Initial clinical experience in 16 cases. Proceedings of the annual conference of the Veterinary Orthopaedic Society; 2008: Big Sky, Montana, USA; March 9–14, 2008.
47. Piermattei DL, Flo GL, DeCamp CE. Handbook of small animal orthopedics and fracture repair. 4 ed. St. Louis: Saunders Elsevier; 2006: 31–42.
48. Rovesti GL, Margini A, Cappellari F, et al. Clinical application of intraoperative skeletal traction in the dog. *Vet Comp Orthop Traumatol* 2006; 19: 14–19.
49. Apivatthakakul T, Arpornchayanon O, Bavonratanevech S. Minimally invasive plate osteosynthesis (MIPO) of the humeral shaft fracture. Is it possible? A cadaveric study and preliminary report. *Injury* 2005; 36: 530–538.
50. Livani B, Belangero WD. Bridging plate osteosynthesis of humeral shaft fractures. *Injury* 2004; 35: 587–595.
51. Wenda K, Runkel M, Degreif J, et al. Minimally invasive plate fixation in femoral shaft fractures. *Injury* 1997; 28 Suppl 1: A13–19.
52. Ziran BH, Belangero W, Livani B, et al. Percutaneous plating of the humerus with locked plating: technique and case report. *J Trauma* 2007; 63: 205–210.
53. Smith J, Berry G, Laflamme Y, et al. Percutaneous insertion of a proximal humeral locking plate: an anatomic study. *Injury* 2007; 38: 206–211.
54. Laflamme GY, Rouleau DM, Berry GK, et al. Percutaneous humeral plating of fractures of the proximal humerus: results of a prospective multicenter clinical trial. *J Orthop Trauma* 2008; 22: 153–158.
55. Oh CW, Park BC, Kyung HS, et al. Percutaneous plating for unstable tibial fractures. *J Orthop Sci* 2003; 8: 166–169.
56. Redfern DJ, Syed SU, Davies SJ. Fractures of the distal tibia: minimally invasive plate osteosynthesis. *Injury* 2004; 35: 615–620.
57. Schmokel HG, Hurter K, Schawalder P. Percutaneous plating of tibial fractures in two dogs. *Vet Comp Orthop Traumatol* 2003; 16: 191–195.
58. Ruedi TP, Sommer C, Leutenegger A. New techniques in indirect reduction of long bone fractures. *Clin Orthop Relat Res* 1998; 347: 27–34.
59. Wong EW, Lee EW. Percutaneous plating of lower limb long bone fractures. *Injury* 2006; 37: 543–553.
60. Beale BS, Hulse DA, Schulz KS, et al. Small animal arthroscopy. Philadelphia: Saunders; 2003: 78.
61. Weiss DB, Kaar SG, Frankenburg EP, et al. Locked versus unlocked plating with respect to plate length in an ulna fracture model. *Bull NYU Hosp Jt Dis* 2008; 66: 5–8.
62. Sanders R, Haidukewych GJ, Milne T, et al. Minimal versus maximal plate fixation techniques of the ulna: the biomechanical effect of number of screws and plate length. *J Orthop Trauma* 2002; 16: 166–171.
63. Cabassu JP. Elastic plate osteosynthesis of femoral shaft fractures in young dogs. *Vet Comp Orthop Traumatol* 2001; 14: 40–45.
64. Sarrau S, Meige F, Autefage A. Treatment of femoral and tibial fractures in puppies by elastic plate osteosynthesis. A review of 17 cases. *Vet Comp Orthop Traumatol* 2007; 20: 51–58.
65. Keller MA, Voss K, Montavon PM. The ComPact UniLock 2.0/2.4 system and its clinical application in small animal orthopedics. *Vet Comp Orthop Traumatol* 2005; 18: 83–93.
66. Aguila AZ, Manos JM, Orlansky AS, et al. In vitro biomechanical comparison of limited contact dynamic compression plate and locking compression plate. *Vet Comp Orthop Traumatol* 2005; 18: 220–226.
67. Schwandt CS, Montavon PM. Locking compression plate fixation of radial and tibial fractures in a young dog. *Vet Comp Orthop Traumatol* 2005; 18: 194–198.
68. Post C, Guerrero T, Voss K, et al. Temporary trans-articular stabilization with a locking plate for medial shoulder luxation in a dog. *Vet Comp Orthop Traumatol* 2008; 21: 166–170.
69. Bone LB. Indirect fracture reduction: A technique for minimizing surgical trauma. *J Am Acad Orthop Surg* 1994; 2: 247–254.
70. Leunig M, Hertel R, Siebenrock KA, et al. The evolution of indirect reduction techniques for the treatment of fractures. *Clin Orthop Relat Res* 2000; 375: 7–14.
71. Reems MR, Beale BS, Hulse DA. Use of a plate-rod construct and principles of biological osteosynthesis for repair of diaphyseal fractures in dogs and cats: 47 cases (1994–2001). *J Am Vet Med Assoc* 2003; 223: 330–335.

72. Hulse D, Hyman W, Nori M, et al. Reduction in plate strain by addition of an intramedullary pin. *Vet Surg* 1997; 26: 451–459.
73. Rovesti GL, Margini A, Cappellari F, et al. Intraoperative skeletal traction in the dog: a cadaveric study. *Vet Comp Orthop Traumatol* 2006; 19: 9–13.
74. Oh CW, Oh JK, Kyung HS et al. Double plating of unstable proximal tibial fractures using minimally invasive percutaneous osteosynthesis technique. *Acta Orthop* 2006; 77: 524–530.
75. Hedequist DJ, Sink E. Technical aspects of bridge plating for pediatric femur fractures. *J Orthop Trauma* 2005; 19: 276–279.
76. Oh JK, Oh CW, Jeon IH, et al. Percutaneous plate stabilization of proximal tibial fractures. *J Trauma* 2005; 59: 431–437.
77. Lau TW, Leung F, Chan CF, et al. Wound complication of minimally invasive plate osteosynthesis in distal tibia fractures. *Int Orthop* 2007; 32: 697–703.